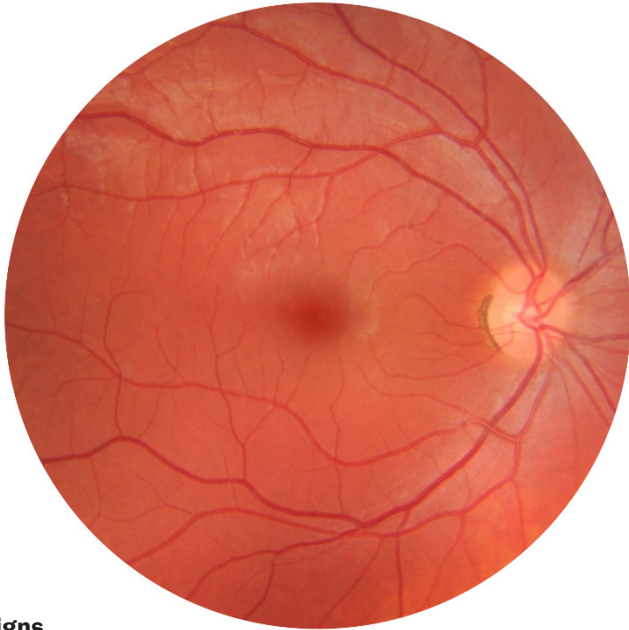


# Diabetic Retinopathy Guide

The following staging guidelines and referral recommendations are adapted from the *International Clinical Diabetic Retinopathy and Diabetic Macular Edema Disease Severity Scales*, the *National Health and Medical Research Council (NHMRC) Guidelines for Management of Diabetic Retinopathy* and *A guide for General Practitioners on the use of Digital Retinal Photography* developed by Optometry Australia (OA).

## No diabetic retinopathy



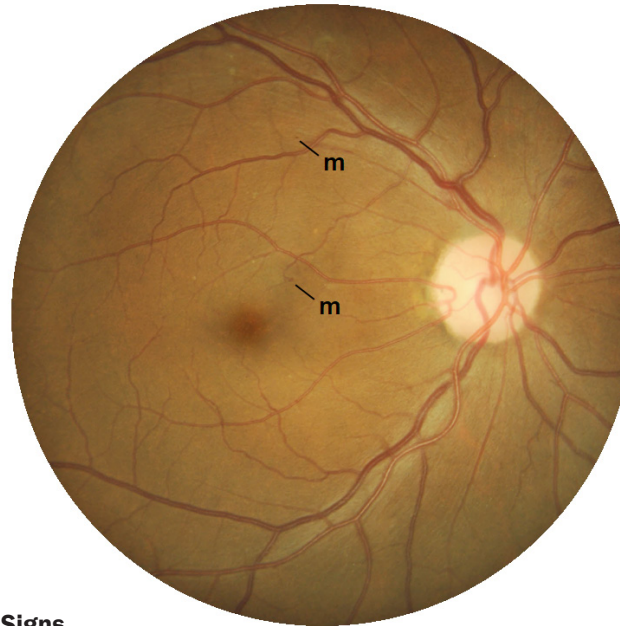
### Signs

No diabetic retinopathy seen

### Management

Refer for a comprehensive examination with an optometrist within 1 year

## Mild diabetic retinopathy



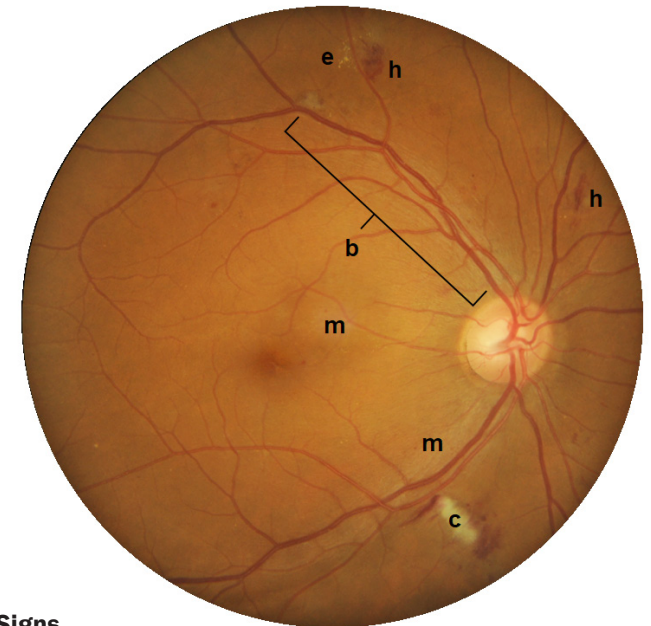
### Signs

Microaneurysms (m): small outpouchings of the blood vessel walls – appear as small red spots

### Management

Refer to an optometrist within 3 months

## Moderate diabetic retinopathy



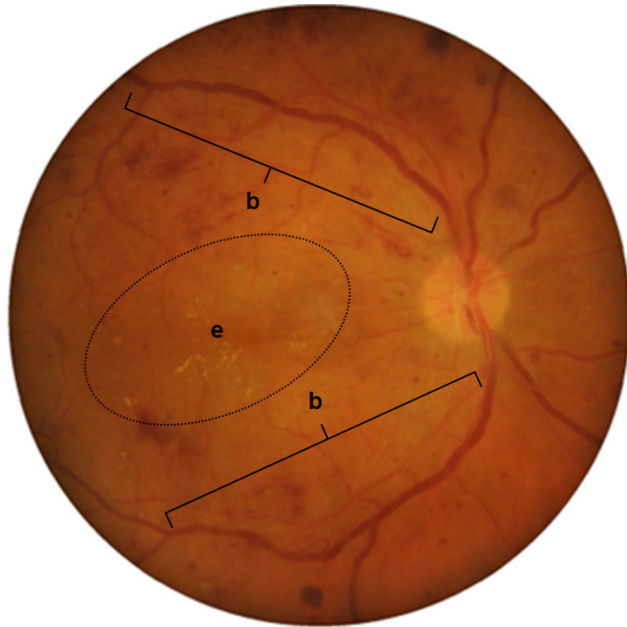
### Signs

- Microaneurysms (m)
- Haemorrhages (h): bleeding due to damaged blood vessels – can be flame, dot or blot shaped
- Hard exudates (e): fatty deposits due to leakage of blood vessels and swelling of the retina – well defined yellow lesions or spots
- Cotton wool spots (c): swelling of the nerve fibre layer due to reduced oxygen – appear fluffy white
- Blood vessel changes (b): due to reduced oxygen supply – blood vessels appear irregular and may loop

### Management

Refer to an optometrist\* or ophthalmologist\*\* within 3 months

## Severe diabetic retinopathy



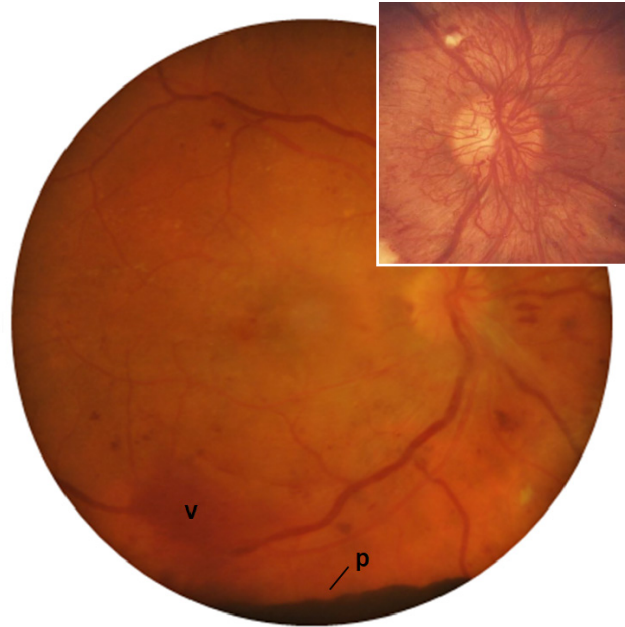### Signs

As with moderate diabetic retinopathy, but more widespread microaneurysms, haemorrhages, blood vessel changes (b), exudate (e), and/or cotton wool spots

### Management

Refer to an ophthalmologist within 4 weeks

## Proliferative diabetic retinopathy



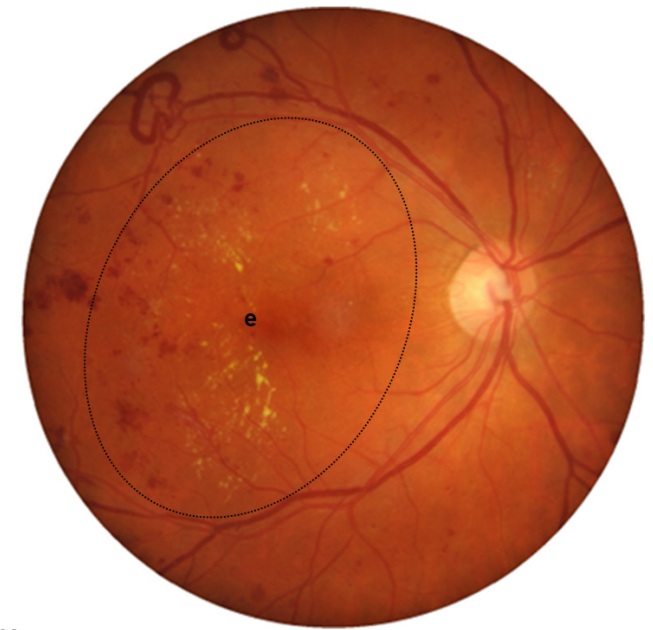### Signs

- Neovascularisation (inset): new blood vessels prone to leakage – appear fan-like and feathery
- Pre-retinal haemorrhage (p): bleeding in front of the retina – typically well-defined and dark coloured
- Vitreous haemorrhage (v): bleeding into the jelly inside the eye – appears hazy and blocks view of the underlying retina

### Management

Refer to an ophthalmologist within 1 week

## Macular oedema



### Signs

- Macular oedema: swelling of the macula
  - Often indicated by the presence of hard exudate (e) in the macula area
  - Swelling may occur without exudate – macula may have a cloudy appearance (difficult to visualise in a photograph)
- Can occur at **ANY** stage

### Management

Refer to an ophthalmologist within 4 weeks

National Health and Medical Research Council Guidelines for Management of Diabetic Retinopathy (2008) [https://www.nhmrc.gov.au/\\_files\\_nhmrc/publications/attachments/di15.pdf](https://www.nhmrc.gov.au/_files_nhmrc/publications/attachments/di15.pdf)

Optometry Australia A guide for General Practitioners on the use of Digital Retinal Photography (2017) [http://www.optometry.org.au/media/871149/gp\\_retinopathy\\_flowchart\\_a4\\_2017.pdf](http://www.optometry.org.au/media/871149/gp_retinopathy_flowchart_a4_2017.pdf)

Wilkinson, C. P., Ferris, F. L., III, Klein, R. E., Lee, P. P., Agardh, C. D., Davis, M., Dills, D., Kampik, A., Pararajasegaram, R. and Verdaguer, J. T. (2003) Proposed international clinical diabetic retinopathy and diabetic macular edema disease severity scales. *Ophthalmology*. 110(9), 1677-1682